

# Guideline

## Peri-Orbital and Orbital Cellulitis: Emergency Management in Children

Document ID	CHQ-GDL-00723	Version no.	3.0	Approval date	16/10/2023
Executive sponsor	Executive Director Medical Services			Effective date	10/11/2023
Author/custodian	Director of Emergency Medicine			Review date	16/10/2027
Supersedes	2.0				
Applicable to	Medical and Nursing working in Children's Health Queensland				
Authorisation	Executive Director Clinical Services QCH				

### Purpose

This evidence-based guideline provides clinical practice advice for clinicians involved in the emergency management of children with Peri-Orbital and Orbital cellulitis.

### Scope

This guideline applies to all Queensland Health Hospital and Health Services Staff involved in the care and management of children with Peri-Orbital and Orbital cellulitis.

### Related documents

#### Procedures, Guidelines, Protocols

[CHQ-GDL-01202 Children's Health Queensland Paediatric Antibiocard: Empirical Antibiotic Guidelines](#)

[CHQ-GDL-63012 CHQ Hospital In the Home antibiotic guidelines](#)

[CHQ-PROC-01035 Antimicrobial Restrictions](#)

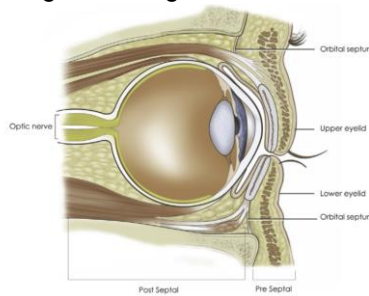
[CHQ-GDL-01057 Antimicrobial treatment: Early intravenous to oral switch - Paediatric Guideline](#)

## Guideline

### Introduction

Infection of the skin and other soft tissues, in and surrounding the eye, is sometimes referred to by the umbrella term, 'Peri-Orbital Cellulitis' <sup>1,2,3,4,5</sup>. This can be confusing, as the term encompasses a range of disease processes, each with differing aetiologies and prognoses. It is important to understand the anatomy of the orbit, in order to appreciate the pathophysiology of infection in this area. Arising from the orbital rim is a tough fibrous layer of fascia, the 'Orbital Septum'. This attaches to the tarsal plates of the eyelids, and provides a physical barrier to infection between the superficial structures of the face, and the deep orbital structures <sup>1,2,3,4,6,7,8,9,10</sup>. The infection will therefore usually occur in either the pre-septal, or post-septal tissues. Infections in the pre-septal region are most often referred to as 'Peri-Orbital Cellulitis' <sup>1,2,3,11,12</sup>, whilst infections in the post-septal region, involving the orbit and its contents, are commonly referred to as 'Orbital Cellulitis' <sup>1,2,3,11,12</sup>. These terms will be used in this guideline.

Figure 1: Sagittal Cross Section of Orbit <sup>1</sup>



All children with either 'Peri-Orbital (pre-septal)' or 'Orbital (post-septal)' Cellulitis will present with erythema and swelling of the eye and/or surrounding skin. The underlying disorder can often be very difficult to distinguish clinically <sup>2,3,6,13,14</sup>.

Peri-Orbital Cellulitis occurs due to local infection of the skin of the face <sup>4</sup>. This can be due to a superficial infection of the eyelids, such as dacryocystitis, or a sty <sup>1,2,8,14,15</sup>. It can also occur following a break in the skin of the face, such as an insect bite, or wound <sup>2,7,8,14,15</sup>. The most common organisms causing these infections are *Streptococcus pyogenes*, *Staphylococcus epidermidis*, and *Staphylococcus aureus* <sup>6,8,9,15,16</sup>.

Orbital Cellulitis is usually a complication of sinus disease <sup>1,2,4,5,8,9,11,12,13,14,15,17,18</sup>, orbital trauma, or less often, occurs via direct haematological spread <sup>1,8,9,11,15</sup>. The infection spreads most frequently from the ethmoid sinuses <sup>1,10,11,12,13,14</sup>. These lie directly medial to the orbits, and are separated by a thin bone layer, the lamina papyracea <sup>1,2,3,4,6,7,11,14,19</sup>. The most common causative organisms are *Streptococcus pneumoniae*, *Staphylococcus aureus*, *Streptococcus pyogenes*, *Staphylococcus epidermidis*, and *Haemophilus* species <sup>1,2,3,4,5,6,8,9,10,11,13,15,16,17,18,19</sup>. Prior to immunisation against *Haemophilus influenzae* type B (HIB), this was a common cause of Orbital Cellulitis in children <sup>2,11,14,16,17</sup>.

Orbital Cellulitis is a sight, and potentially life-threatening, disease <sup>3,9,13,14</sup>. Infection within the orbit can lead to direct compression of the optic nerve causing blindness <sup>1,2,12,13,14</sup>. The infection may also spread into surrounding tissues and cause a sub-periosteal, or orbital abscess. If the infection spreads posteriorly via the valveless veins of the orbit, it can cause cavernous sinus thrombosis, intra-cerebral abscess or meningitis <sup>1,2,3,4,5,6,8,10,11,13,14,18,19</sup>. As Orbital Cellulitis is primarily a disease of the sinuses, patients are cared for by an Ear, Nose and Throat (ENT) team<sup>19</sup>, with Ophthalmology team consultation, and involvement of other multi-disciplinary teams as required.

## Assessment

A thorough clinical assessment is required in all patients presenting with redness and swelling around the eye, to help determine the severity, and location (pre or post-septal) of any infection.

Ensure **adequate analgesia** (may require opiates). A child in pain will be difficult to examine thoroughly<sup>4</sup>.

## History

- Age of patient (Peri-Orbital cellulitis more common in younger patients less than 5yrs<sup>1,4,8,10,15</sup>)
- Recent infections (upper respiratory tract infection, sinus, teeth, ears)?
- Eye problems (nasolacrimal duct obstruction, dacrocystitis, stye, chalazion, watery eye)?
- Injury to eyes, face or skin (insect bites, penetrating injury, eczema)?
- Recent surgery to eyes, nasolacrimal ducts (probe/ syringe), teeth, or sinuses?
- Immunisation status (especially *HIB*)?
- Co-morbidities (immune-compromise, diabetes)?
- Risk for non-multi resistant Methicillin Resistant Staphylococcus Aureus (nmMRSA)
  - previous nmMRSA, history of boils, Aboriginal or Pacific Islander Descent?
- Personal or family history of boils?
- Symptoms:
  - Redness and swelling around eye
  - Eye pain
  - Headache
  - Fever
  - Neurological symptoms (drowsy, altered level of consciousness)

## Examination

- General appearance (toxic or shocked)
- Temperature and other vital signs
- Neurological examination in the presence of altered conscious level
- Evidence of skin lesion/ wound as source for skin infection
- Eye:
  - Eyelids and surrounding skin (extent of erythema and swelling)
  - Conjunctiva (injection, chemosis, discharge)
  - Sclera (injection)
  - Proptosis
  - Eye movements (reduced movement, pain, diplopia)
  - Visual Acuity (use Snellen or Lea chart, as age-appropriate)

- Visual Fields
- Colour Vision, specifically perception of Red (can use Ishihara colour plates if available)
  - Note: Loss of red-colour perception is an early sign of optic nerve injury.*
- Pupil size and reaction (include checking for relative afferent pupil defect [RAPD])
- Fundoscopy

### Investigations

If clinical assessment is sufficient to diagnose peri-orbital erythema and swelling of a non-infectious cause, such as allergy, then no investigations are required, and the patient should be managed according to the clinical diagnosis. A thorough clinical assessment may also be sufficient to diagnose mild cases of infectious peri-orbital cellulitis, in which case, any investigation requests can be tailored to the patient.

- **Swab of any conjunctival discharge** for Microscopy & Sensitivity (MC&S) <sup>3,4,5,9,11,14,15,18</sup> with swabs for *Chlamydia* and *Gonorrhoea* in neonates
- **Blood Tests** <sup>5</sup>: Full Blood Count (FBC) <sup>4,9,11,14,16</sup>, C-Reactive Protein (CRP) <sup>4,14</sup>, Blood Cultures <sup>4,9,11,14,15,16</sup>
  - FBC and CRP may help differentiate between moderate peri-orbital, and severe peri-orbital or orbital cellulitis
  - Blood cultures may help direct antibiotic therapy in more severe infections
- Consider lumbar puncture if clinical concern for meningitis (*caution re: raised intracranial pressure*) <sup>9,11,16</sup>
- **Medical Imaging**

Usually best to be considered in consultation with ENT team, in order to limit radiation exposure <sup>2,17,18</sup>. Medical imaging is used to help to delineate the source of the infection, as well as diagnose complications (such as abscess) that may require surgical intervention.

*(Note: Some patients may require general anaesthetic, due to young age.)*

- **Computerised Tomography (CT) of orbits, brain and sinuses, WITH contrast.**
  - Initial imaging choice in the majority of cases <sup>2,3,4,5,6,8,9,10,11,12,13,14,15,16,18,19</sup>.
  - Important to delineate size of abscess as > 3.8mL may need surgical intervention
  - Presence of cavernous sinus thrombosis is likewise an indication for surgery.
- Magnetic Resonance Imaging (MRI) brain and sinuses <sup>2,3,9,11,12,13,14,17,18,20</sup>
  - Gives less definition of bony disease, better for assessing intracranial complications.
- Bedside Ultrasound may be considered (*in experienced hands only and will still require a CT*)
  - Can help delineate pre-septal, and post-septal infection <sup>14,19,22</sup>.

**ALERT – If high-risk features are present, will require urgent medical imaging:** <sup>2,3,4,6,8,10,12,18,19</sup>



- **Altered level of consciousness/ seizure**
- **Gross proptosis (especially with marked conjunctival chemosis)**
- **Ophthalmoplegia (reduced eye movements)**
- **Altered visual acuity or loss of red-colour perception**
- **Abnormal pupil response, or afferent pupil defect**
- **No clinical improvement, or deterioration, after 24hrs of appropriate intravenous antibiotics**

Diagnosis

Symptoms and signs for differentiating Periobital and Orbital Cellulitis	
Infection Severity	Symptoms
<b>MILD</b>	<p>Age more than 3 months <sup>2</sup> (if age less than 3 months, treat at minimum as 'moderate')</p> <p>Not immune-compromised</p> <p>Erythema and swelling around eye, minimal involvement of the eyelid <sup>2</sup>. Note repeated rubbing and insect bites can cause eyelid trauma and therefore swelling.</p> <p>Patient able to fully open, and allow Doctor to examine eye <sup>2</sup></p> <p>White sclera, with non-injected conjunctiva</p> <p>Eye movements normal, with no pain <sup>7,8,9</sup></p> <p>Vision intact (red-colour perception, fields and acuity) <sup>8,9</sup></p> <p>No fever <sup>2,7</sup></p> <p>White Cell Count (WCC), if tested, is normal <sup>7</sup></p>
<b>MODERATE</b>	<p>As above with <b>MILD</b> but more extensive erythema and swelling around eye and eyelid</p> <p>No risk Factors for nmMRSA</p>
<b>SEVERE</b> <i>(Note: If not able to open eye for assessing eye movements and pupils, then assume diagnosis is ORBITAL Cellulitis) <sup>2,9,14,15</sup></i>	<p>As above with <b>MODERATE</b> but more extensive erythema and swelling</p> <p>Doctor able to fully open eye, and to examine eye</p> <p>White sclera, with non-injected conjunctiva</p> <p>Eye movements normal, with no pain <sup>1,7,8</sup></p> <p>Vision intact (red-colour perception, fields and acuity) <sup>8</sup></p> <p>Possible fever</p> <p>WCC may be elevated</p> <p>Medical imaging confirming pre-septal infection</p>
<b>ORBITAL</b>	<p>Erythema and swelling around eye and eyelid (may not be extensive in early stage) <sup>5,7,9,11</sup></p> <p>Injection of sclera, and conjunctiva</p> <p>Chemosis of conjunctiva <sup>1,2,5,7,9,15</sup> (<b>late sign</b>)</p> <p>Eye movements decreased <sup>2,5,6,7,11,15,16</sup>, and painful <sup>9,10</sup> (<b>late sign</b>)</p> <p>Vision change (late sign = optic nerve compression) <sup>2,3,5,7,9,15,16</sup></p> <p>Altered pupil response (late sign = optic nerve compression) <sup>2,3,9,11</sup></p> <p>Diplopia (<b>late sign</b>) <sup>1,3,6,9,11</sup></p> <p>Proptosis (<b>late sign</b>) <sup>1,2,3,6,7,9,10,11,15,16</sup>,</p> <p>Fever <sup>2,3,5,6,9,11</sup></p> <p>WCC elevated <sup>3,7,10,11,14,15</sup></p> <p>Headache and Nausea <sup>3,6,9,11,16</sup></p> <p>Risk factors for Orbital Cellulitis (Eye surgery, Sinus disease <sup>15</sup>, Non <i>HIB</i>-immunised, Immune-compromise <sup>2</sup>)</p>



**ALERT – Diagnosis based on clinical findings can be very difficult** <sup>2,3,6,8,13,14,19</sup>.

If in doubt, treat with intravenous antibiotics, and refer for ENT (and Ophthalmology) opinions immediately <sup>2</sup>.

## Management



**ALERT – DO NOT DELAY** starting intravenous antibiotics if considering Severe Peri-Orbital or Orbital Cellulitis <sup>5,14,18</sup>. Early treatment with antibiotics may be sight, or life-saving.

For antibiotic choice and dosing for the management of Periorbital and Orbital cellulitis, refer to the [CHQ-GDL-01202 Children's Health Queensland Paediatric Antibiocard: Empirical Antibiotic Guidelines](#).



### ALERT –

If **ORBITAL** Cellulitis, and signs of optic nerve compression:

- Inability to spontaneously open or close eyelids,
- Proptosis,
- External ophthalmoplegia,
- Decreased visual acuity/ red perception,
- RAPD,
- Increased intraocular pressure,

**= Orbital Compartment Syndrome.**

**Requires URGENT surgical decompression (lateral canthotomy)** <sup>2,4,9,11,18</sup>.

**Request immediate Ophthalmology team advice +/- attendance.**

## Disposition

All children with a diagnosis of Peri-Orbital or Orbital Cellulitis, other than MILD disease, must be admitted to the hospital 3,4,19. Most cases can be managed at a regional hospital, with local ENT (+/- Ophthalmology) consultation. If no local ENT service available, should be discussed with regional referral centre.

### - MILD Peri-Orbital Cellulitis

- Give first dose of **oral** antibiotic in the Emergency Department (ED), and write prescription for ongoing medication. Must complete **minimum of 7 days of oral antibiotic therapy** 1,6,8,9,14,16,24
- Ensure **sufficient** volume of liquid antibiotics prescribed (calculate exact volume needed, may require prescription for multiple bottles), and parents aware of need to **complete full course**.
- Must have **thorough** history and examination documented, and included on discharge paperwork 4.
- Advise parents of signs of deterioration, and reasons for urgent return to ED (including being unable to administer medication regularly).
- All children **must** have review by a doctor within 24 hours of discharge. If the child is not able to attend own General Practitioner/ Local Medical Officer, then arrange for review in the ED 2,4,9,11. If concerns about reliable follow-up, then admit to SSU/ ward overnight.
- Discuss with ENT (and Ophthalmology) teams only if re-presentation to the ED despite antibiotic therapy.

### - MODERATE Peri-Orbital Cellulitis

- Refer to a General Paediatric team for admission or referral to HITH if within catchment.
- **Intravenous** antibiotic therapy to be continued for **minimum of 48 hours** 23.
- All children must have a daily medical review, with examination of optic nerve function (pupil reaction, visual acuity, colour vision), and eye movements 1,4,13,19. Any signs of deterioration require urgent review by ENT (and Ophthalmology) teams.
- If improving clinically (erythema and swelling decreased, fever and WCC improved), then discharge home on oral antibiotics (as per MILD) after completion of 48 hours of intravenous therapy. 6,9,24

### - SEVERE Peri-Orbital Cellulitis

- **Urgent referral** to ENT +/- Ophthalmology teams 1,2,3,4,9,12,14,16,18
- Consider need for medical imaging if clinical diagnosis (Peri-Orbital vs. Orbital) not clear.
- Admission under ENT team (may require inter-hospital transfer if no local service), with ongoing Ophthalmology team review.
- **Intravenous** antibiotic therapy to be continued for **minimum of 48 hours** 24, although may require longer intravenous course (liaise with ID team).



- All children must have a **minimum** of twice daily review with examination of optic nerve function (pupil reaction, visual acuity, colour vision), and eye movements <sup>1,4,13,19</sup>.
- If improving clinically (erythema and swelling decreased, fever and WCC improved), then consider discharging home on oral antibiotics (as per MILD) to complete a total of 14 days of antibiotic therapy. <sup>6,9,24</sup>

- **ORBITAL** Cellulitis

- **Emergent referral** to ENT +/- Ophthalmology teams <sup>1,2,3,4,9,12,14,16,18</sup>.
- Organise medical imaging if high-risk features present, or on advice from ENT team.
- Admission under ENT team (may require inter-hospital transfer if no local service), with ongoing Ophthalmology team review.
- Inpatient treatment with a **minimum of 72 hours of intravenous** antibiotics <sup>23</sup>, and eventual discharge with oral antibiotics to complete total of 14 days of antibiotic therapy <sup>1,2,8,18,24</sup>. Seek ID review of antibiotic therapy after 48 hours.
- Intranasal corticosteroid beconase with nasal douche therapy should be initiated if evidence of sinus disease for 5 days.
- Surgical management will be at the discretion of the treating ENT team, and dependant on the clinical situation.

## Consultation

Guideline prepared and reviewed by:

- Fellow, QCH Emergency Department
- ENT Fellow, CHQ
- Ophthalmology Clinical Fellow, CHQ
- Director of Infectious Diseases, CHQ
- Pharmacist Advanced– Antimicrobial Stewardship, CHQ

## Definition of terms

Term	Definition
Dacrocystitis	Infection of the lacrimal sac, secondary to obstruction of the nasolacrimal duct.
Stye	Inflamed swelling on the edge of an eyelid, caused by infection of the gland at the base of an eyelash.
Chalazion	A cyst in the eyelid that is caused by inflammation of a blocked Meibomian gland, usually on the upper eyelid.
Chemosis	Swelling/oedema of the conjunctiva
Proptosis	Abnormal protrusion or displacement of an eye
Diplopia	Double vision

RAPD	A Relative Afferent Pupillary Defect (Marcus Gunn Pupil) is observed during the swinging-flashlight test whereupon the patient's pupils constrict less (therefore appearing to dilate) when a bright light is swung from the unaffected eye to the affected eye.
Lateral Canthotomy	Emergent orbital decompression by incision of the lateral canthal tendon

## References and suggested reading

1. *Preseptal and Orbital Cellulitis in Children*. **Watts, P.** Paediatrics and Child Health: 2015; **26:1**; pp1 – 8
2. *Management of Periorbital and Orbital cellulitis*. **Buchanan, M.A., Muen, W. and Heinz, P.** Paediatrics and Child Health: 2012; **22:2**; pp 72 – 77
3. *Picture Quiz: A Swollen Right Eye in a Child*. **Harris, M.S. and Chawdhary, G.** British Medical Journal (the BMJ): 2015; **350**; h554.
4. *Guidelines for the Management of Patients Suspected to have Periorbital Cellulitis*. **Marshall, A. and Jones, N.S. Nottingham University Hospitals NHS Trust, Nottingham, UK**: Issued June 2013 (Downloaded April 2016) [www.nuh.nhs.uk/handlers/downloads.ashx?id=61117](http://www.nuh.nhs.uk/handlers/downloads.ashx?id=61117)
5. *Clinical Practice Guidelines: Orbital Cellulitis in Children*. **Boston Children's Hospital, Boston, MA, USA**. (Downloaded April 2016) <http://www.childrenshospital.org/conditions-and-treatments/conditions/o/orbital-cellulitis/overview>
6. *Paediatric Pre- and Post-septal Peri-Orbital Infections are Different Diseases. A Retrospective Review of 262 cases*. **Botting, A.M., McIntosh, D. and Mahadevan, M.** International Journal of Pediatric Otorhinolaryngology: 2008; **72**; pp 377 – 383
7. *Periorbital and Orbital Cellulitis in Children*. **Clarke, W.N.** Paediatric Child Health: 2004; Vol 9, No 7; pp 471 – 472
8. *Periorbital and Orbital Cellulitis Summary*. **Rassbach, C. Lucile Packard Children's Hospital, Stanford Children's Health, Palo Alto, CA, USA**: Effective May 2011 (Downloaded April 2016) [http://peds.stanford.edu/Rotations/blue\\_team/documents/Periorbital\\_and\\_Orbital\\_Cellulitis\\_Summary.pdf](http://peds.stanford.edu/Rotations/blue_team/documents/Periorbital_and_Orbital_Cellulitis_Summary.pdf)
9. *Starship Clinical Guidelines: Eye Infections*. **Best, E., Mora, J., and Anson, K. Starship Children's Health, Auckland**: 01 April 2012 <http://www.adhb.govt.nz/StarShipClinicalGuidelines/Documents/Eye%20Infections.pdf>
10. *Acute Periorbital Infections: Who Needs Emergent Imaging?* **Rudloe, T.F., Harper, M.B., Prabhu, S.P., et. al.** Pediatrics: 2010; Vol **125 (4)**; pp 719 – 726
11. *BMJ Best Practice: Peri-orbital and Orbital Cellulitis*. **Kim, H.J., and Kersten, R.** bestpractice.bmj.com; Last updated Feb 12. 2016.
12. *Paediatric Post-Septal and Pre-Septal Cellulitis: 10 Years' Experience at the Tertiary-Level Children's Hospital*. **Mathew, A.V., Craig, E., et. al.** British Journal of Radiology: 2014; **87**; 20130503
13. *Orbital Cellulitis, Orbital Subperiosteal and Intraorbital Abscess. Report of Three Cases and Review of the Literature*. **Vairaktaris, E., Moschos, M.M., Vassiliou, S., et. al.** Journal of Cranio-Maxillofacial Surgery: 2009; Vol **37**; pp 132 – 136
14. *An Evidence Based Review of Periorbital Cellulitis*. **Baring, D.E.C. and Hilmi, O.J.** Clinical Otolaryngology: 2011; **36**; pp 57-64
15. *Preseptal Cellulitis*. **Qaseem, A., and Bond, S.** DynaMed Plus: EBSCO Information Services: Updated 22 July 2015 (Downloaded April 2016)

16. *Clinical Practice Guidelines: Periorbital and Orbital Cellulitis*. **Royal Children's Hospital, Melbourne, Australia**. (Downloaded April 2016)  
[www.rch.org.au/clinicalguide/guideline\\_index/Periorbital\\_and\\_Orbital\\_Cellulitis/](http://www.rch.org.au/clinicalguide/guideline_index/Periorbital_and_Orbital_Cellulitis/)
17. *A Complicated Case of Orbital Cellulitis: When the Fog Doesn't Clear*. **Raj, C and Lim-Joon, T**. *Journal of Paediatrics and Child Health*: 2015; **51**; pp 552 – 554
18. *Orbital Cellulitis – Guidelines on Best Management*. **Morris, S. Gold Coast University Hospital, Gold Coast Hospital and Health Service, Australia**: Effective 25 May 2015 (Downloaded April 2016)
19. *Guidelines for the Management of Periorbital Cellulitis/ Abscess*. **Howe, L. and Jones, N.S**. *Clinical Otolaryngology*: 2004; **29**; pp725 – 728
20. *Management of Pediatric Orbital Cellulitis: a systematic review*. **Wong, S.J, and Levi J**. *International Journal of Pediatric Otorhinolaryngology*: 2018; **110**; pp123-129
21. *MRI of Orbital Cellulitis and Orbital Abscess: The Role of Diffusion-Weighted Imaging*. **Sepahdari, A.R., Aakalu, V.K., Kapur, R., et. al**. *American Journal of Roentgenology*: 2009; Vol **193**; pp W244 – W250
22. *Using Orbital Sonography to Diagnose and Monitor Treatment of Acute Swelling of the Eyelids in Pediatric Patients*. **Mair, M.H, Geley, T., Judmaier, W., and GaSner, I**. *American Journal of Roentgenology*; 2002; Vol **179**; 1529 – 1534
23. CHQ Paediatric Antibiocard: Empirical Antibiotic Guidelines. Clark, J., Nourse, C. and Graham, N. Effective 14 January 2016 (Downloaded April 2016) [CHQ Paediatric Antibiocard: Empirical Antibiotic Guidelines \(CHQ-GDL-01202\)](#)
24. *Antibiotic duration and timing of the switch from intravenous to oral route for bacterial infections in children: systematic review and guidelines*. **McMullan, B.J., Andresen, D., Blyth, C.C., et. al**. *The Lancet Infectious Diseases* (Online First): Published 16 June 2016

## Guideline revision and approval history

Version No.	Modified by	Amendments authorised by	Approved by
1.0 18/01/2019	Director, Paediatric Emergency Medicine	Divisional Director, Critical Care	Executive Director Hospital Services
2.0 08/05/2020	Staff Specialist, Paediatric Emergency Medicine Director, Infection Management and Prevention Services Medical Lead, Antimicrobial Stewardship (QCH), ENT and Ophthalmology fellows	Medicines Advisory Committee (CHQ)	Executive Director Clinical Services (QCH)
3.0 16/10/2023	Staff Specialist Emergency	Divisional Director Critical Care	Executive Director Clinical Services

### Keywords

Peri-Orbital Cellulitis, Orbital Cellulitis; AMS, antimicrobial stewardship, HITH, hospital in the home, flucloxacillin, cefalexin, trimethoprim / sulfamethoxazole, cefotaxime, cefazolin, lincomycin, clindamycin, 00723

### Accreditation references

NSQHS Standards:  
Standard 3: Preventing and Controlling Healthcare-Associated Infection  
Standard 4: Medication Safety

Appendix:

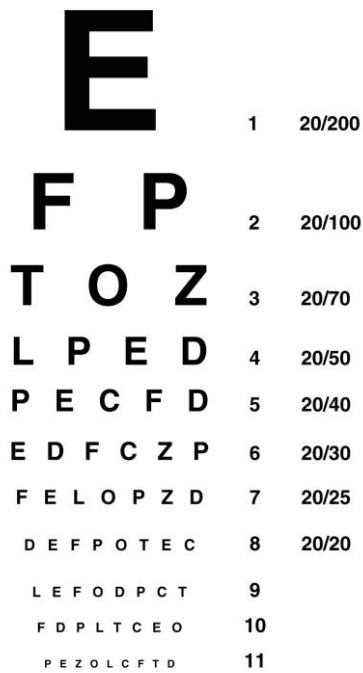


Figure 2: Example of Snellen Chart (not to scale)

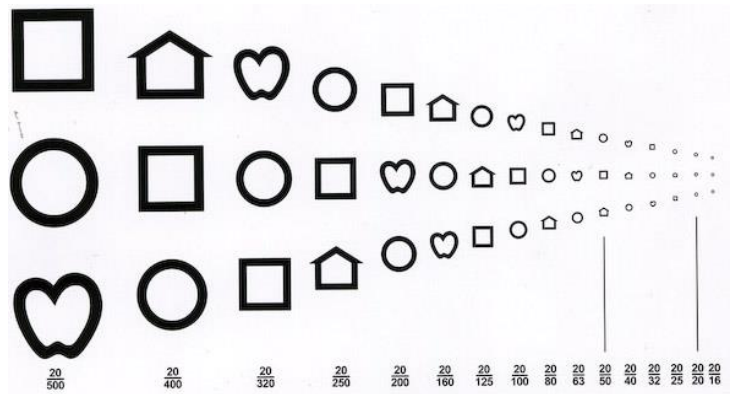


Figure 3: Example of Lea Chart (not to scale)



Figure 4: Example of Ishihara Colour Plate (not to scale)