

Guideline

Acute management of Open Globe Injuries

Document ID	CHQ-GDL-01074	Version no.	3.0	Approval date	21/11/2022
Executive sponsor	Executive Director Medical Services			Effective date	21/11/2022
Author/custodian	Director Infection Management and Prevention service, Immunology and Rheumatology			Review date	21/11/2024
Supersedes	2.0				
Applicable to	All Children's Health Queensland (CHQ) staff				
Authorisation	Executive Director Clinical Services				

Purpose

This evidence-based guideline provides clinical practice advice for clinicians for the acute management of children with open globe injuries. A paediatric ophthalmology team must be actively involved in the management of all patients presenting with this condition.

Scope

This guideline applies to all Children's Health Queensland (CHQ) Staff treating a child presenting for the management of open globe injury.

Related documents

- [CHQ-GDL-01202 CHQ Paediatric Antibiocard: Empirical Antibiotic Guidelines](#)
- [CHQ-PROC-01035 Antimicrobial Restrictions](#)
- [CHQ Antimicrobial Restriction list](#)
- [CHQ-GDL-01023 Tetanus Prophylaxis in Wound Management](#)

Guideline

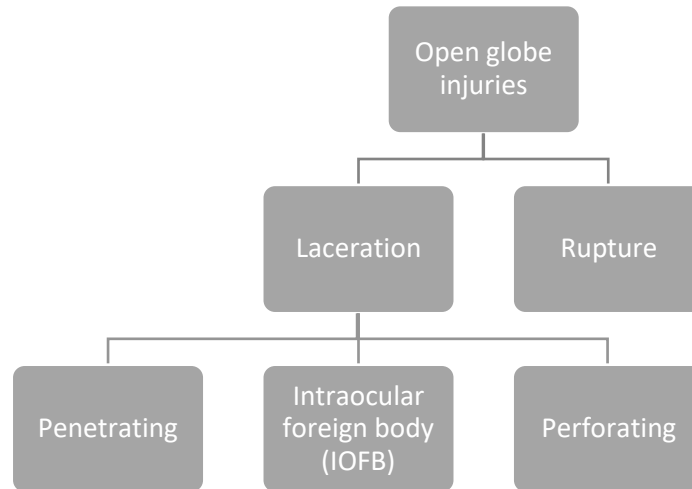
Introduction

Ocular trauma is an important cause of eye morbidity and is a leading cause of non-congenital mono-ocular blindness among children.¹ A quarter of a million children present each year with serious ocular trauma. The vast majority of these are preventable.²

Open globe injuries are injuries where the cornea and/or sclera are breached and there is a full-thickness wound of the eye wall.³ It can be further delineated into globe rupture from blunt trauma and lacerations from sharp objects.

When a large blunt object impacts onto the eye, there is an instant increase in intraocular pressure and the eye wall yields at its weakest point leading to tissue prolapse.⁴

Open globe lacerations are caused by sharp objects or projectiles and subdivided into either penetrating or perforating injuries. A penetrating injury only has an entrance wound or the same entrance/exit wound, while a perforating injury has separate entrance and exit wounds. An intraocular foreign body is usually associated with penetrating injuries and can be present anywhere inside the interior of the globe.⁴



Paediatric open globe injuries most commonly occur at home and are frequently from penetration with sharp objects e.g. scissors, knives, sticks, thorns or writing implements.⁵ In addition, teenage boys often suffer from penetrating eye injuries from air powered pellet guns or blunt trauma from ball sports, motor vehicle accidents or fights.⁴

Endophthalmitis is an infection of the eyeball (globe) and is a serious complication of open globe injuries and is associated with a significantly worse final visual acuity. The incidence of endophthalmitis from traumatic injuries in children ranges from 4.9% to 54.2%.⁵ Risk factors for endophthalmitis include the presence of an intraocular foreign body (IOFB), delayed presentation (more than 24hrs post injury), wound contamination and involvement of the lens capsule.⁶

Assessment

History

- Accurate and full history of event
 - Mechanism
 - High risk eye trauma: high velocity projectile, high impact blunt trauma or injury from a sharp object, contamination with plant material/soil
 - Timing
 - Witnesses
 - Composition of any possible intraocular foreign body (IOFB), if known
- Regular medications
- Allergies
- Time of last meal
- Prior ocular conditions

- Prior ocular surgeries
- Tetanus immunization status
- Co-morbidities (immune-compromised, diabetes)?
- Symptoms

Examination

AVOID any examination that may apply pressure to eyeball e.g. eyelid retraction or intraocular pressure measurement by tonometry.

May need to examine under procedural sedation or anaesthetic if child is not cooperative to examination.

Avoid administering any medication (e.g. amethocaine/tetracaine) or diagnostic eye drops (e.g. fluorescein) into eye in cases of obvious or high likelihood globe rupture

Any protruding foreign body should be left in-situ

- Inspection
- Visual acuity
- Relative afferent pupillary defect
- Colour vision
- Full ophthalmic examination (motility, colour vision, IOP, anterior segment, dilated fundus) in uninvolved eye to provide basis for comparison, to ensure no damage to “good” eye, and to assist in monitoring for future treatments
- Examine adjacent structures for injury e.g. orbital, skull fractures

Assessment (continued)

Examination (continued)

Physical signs of a globe rupture or laceration:

- Markedly decreased visual acuity
- Relative afferent pupillary defect
- Eccentric or teardrop pupil
- Increased or decreased anterior chamber depth
- Extrusion of vitreous
- External prolapse of the uvea (iris, ciliary body, or choroid) or other internal ocular structures
- Tenting of the cornea or sclera at the site of globe puncture
- Low intraocular pressure
- Seidel sign – fluorescein streaming in a tear drop pattern away from the puncture site
- Deep / large subconjunctival haemorrhage

Investigations

Open globe injuries are generally diagnosed clinically but imaging may be helpful to detect the presence of an intraocular foreign body if suspected, or to evaluate the extent of globe injury. The main modalities used are CT and MRI scan, X ray is rarely used. These are listed in order of preference, below:

- CT scan (non-contrast 1 to 2 mm cuts axial and coronal through the orbits)
 - Pros: highly sensitive for metallic IOFBs, and more sensitive than MRI for glass
 - Cons: potential for motion artefact and potentially harmful dose of radiation to lens; limited ability to visualize materials such as wood, ceramics and plastics.
- MRI
 - Pros: Helpful for non-metallic IOFB that are radiolucent on CT.
 - Cons: Must not be used if there is a possibility of a metallic IOFB
- X-ray
 - Pros: Rapid, cost-effective, sensitive for metallic IOFB and orbital fractures
 - Cons: Poor resolution; not used when more advanced imaging modalities available

Management

Initial management

- Eye shield over affected eye and avoidance of any eye manipulation
- Bed rest (head of bed elevated to 30 degrees if haemodynamic condition allows)
- Avoidance of eye medication administration
- Analgesia and anti-emetics
- Keep fasted
- [Tetanus prophylaxis](#) – consider nature of wound, time since last immunisation

Table 1: Empirical antimicrobials in open globe injury

Open globe injury (including blunt or penetrating eye injury +/- endophthalmitis)	Topical (Table 2)	Topical antibiotics can only be used if prescribed by ophthalmology team after their review of patient. Ofloxacin 3mg/mL [#] eye drops 4 times daily for 1 week Plus Cefazolin 5% * eye drops 2-hourly then taper down as per ophthalmologist advice +/- Gentamicin 1.5% eye drops* 6 times daily for 7 days
	Intravitreal (Table 2)	If IOFB or no IOFT with two or more of three risk factors: (Risk factors: delay in primary repair more than or equal to 24 hours, dirty wound, or lens capsule breach) Intravitreal vancomycin (1mg/0.1mL) [^] AND intravitreal ceftazidime (2mg/0.1mL) [^] NOTE: consider risk of complications of intravitreal injection (i.e. suprachoroidal haemorrhage).
CONSIDER If delay to surgical repair or significant risk of infection	Total of 7 days (combination of IV and oral)	Standard protocol: IV Vancomycin 15 mg/kg 6-hourly (maximum 500 mg/dose) (Perform TDM) AND IV Ceftazidime 50mg/kg 8-hourly (maximum 2 g/dose)
		If MRSA suspected or delayed type Penicillin hypersensitivity: Treat as per standard protocol If immediate type Penicillin hypersensitivity (ie anaphylaxis): IV Vancomycin 15 mg/kg 6-hourly (maximum 500 mg/dose) (Perform TDM) AND IV Ciprofloxacin 10 mg/kg 12-hourly (maximum 400 mg/dose)
		IV treatment for 1 to 2 days then, when surgically stable, consider changing to: Ciprofloxacin [%] orally 20 mg/kg 12-hourly (Maximum 750 mg/dose) Or Moxifloxacin [%] orally 10 mg/kg once daily (Maximum 400mg/day) To complete 7 days total antibiotic therapy. Use cultures to guide choices where available. Systemic antibiotics are not the definitive management. Immediate referral to appropriate specialist surgical services is essential.
	Antifungal (Tables 3, 4 and 5)	Prophylaxis not recommended in the absence of clinical or microbiological evidence of fungal infection. Consider with suggestive history e.g. vegetable matter. Seek ID advice.
# Commercial product available * Central Pharmacy compounded product – contact QCH Pharmacy if required ^ Pre-prepared kit available from pharmacy for use – contact QCH Pharmacy (business hours) or the QCH On call Pharmacist via QCH Switchboard (afterhours) if required % Suspension not commercially available – contact QCH Pharmacy for advice on suitable dose manipulation using a tablet. Poor palatability – consider a drink chaser after dose administration.		

Directed antimicrobial therapy

Consider mechanism of injury/exposure and type of foreign body. Antimicrobial therapy should be directed based on microbiological results and clinical assessment, in consultation with Ophthalmologist and Infectious diseases specialist

Table 2: Antibacterial eye preparations

ANTIBACTERIAL			
Agent	Topical	Intravitreal	Intracameral
Vancomycin	5% eye drops*	1mg/0.1mL^	1mg/0.1mL^
Cefazolin	Preserved 5% eye drops*	2.5mg/0.1mL^	1mg/0.1mL^
Ceftazidime	5% eye drops*	2mg/0.1mL^	-
Ofloxacin	3mg/mL eye drops #	-	-

Commercial product available
 * Central Pharmacy compounded product – contact QCH Pharmacy if required
 ^ Pre-prepared kit available from pharmacy for use – contact QCH Pharmacy (business hours) or the QCH On call Pharmacist via QCH Switchboard (afterhours) if required
 Note: Cefalotin eyedrops no longer available

Table 3: Antifungal eye preparations – options and indications

ANTIFUNGAL	Options	Indications⁷
Topical	Natamycin 5% eye drops #@	First choice for treatment of fungal keratitis by yeasts and filamentous fungi. Broad spectrum antifungal activity against yeasts, filamentous fungi (including Fusarium sp) Topical administration produces effective concentrations in the corneal stroma, but not in the intraocular fluid.
	Voriconazole 1% eye drops *	Alternative choice for treatment of fungal keratitis by yeasts and fungi. Active against Aspergillus sp, Candida sp and Dematiaceous moulds. Variable activity against Fusarium sp
Intravitreal	Voriconazole 100 microgram per 0.1mL^	First choice in the treatment of fungal endophthalmitis (by yeasts or filamentous fungi)

Commercial product available
 * Central Pharmacy compounded product – contact QCH Pharmacy if required
 ^ Pre-prepared kit available from pharmacy for use – contact QCH Pharmacy (business hours) or the QCH On call Pharmacist via QCH Switchboard (afterhours) if required
 @ Special access scheme (SAS) Product – complete [SAS form](#) and return to [QCH pharmacy](#) to facilitate supply

In patients with deep fungal keratitis or with intraocular involvement, oral antifungal treatment may be required in addition to topical, intravitreal and/or intracameral antifungal therapy. Seek ID advice on oral antifungal treatment options.

For antifungal dosing and therapeutic drug monitoring guidance, please refer to [CHQ-GDL-01075 Antifungal Prophylaxis and Treatment in Paediatric Oncology Patients and other Immunocompromised Children](#)

Table 4: Penetration of antifungal agents into different parts of the eye⁸

Antifungal agent	Eye		
	Aqueous	Vitreous	Cornea
Fluconazole	Moderate #	Moderate [#]	Moderate [@]
Voriconazole	Moderate [#]	Low [#]	No data
Posaconazole	No data	Low [#]	No data
Itraconazole	Low ^{#@}	Low ^{#@} Inflamed eyes only	Low [@]
Liposomal Amphotericin B	Low [@] (Inflamed eyes only)	Low [@] (Inflamed eyes only)	Low [@] (Inflamed eyes only)
Caspofungin	Low [#] Moderate [@] (Inflamed eyes only)	Low [#]	Moderate [@] (Inflamed eyes only)
Micafungin	Low [@] (Inflamed eyes only)	Low [@] (Inflamed eyes only)	No data
Anidulafungin	Low [@]	Low [@]	No data

Human data; @ Animal data

Low = Below level of detection to ≤ 0.5 times plasma concentration

Moderate = From >0.5 times to ≤ 5 times the plasma concentration

High = From > 5 times plasma concentration

Surgical management

Urgent surgical intervention is essential and should be listed as surgical emergency priority category b (time frame <4 hours). The main aims of surgical management is to close primary wounds, reposition prolapsed ocular contents or debride if greater than 24 hours, remove intraocular foreign bodies, treat and prevent complications to preserve visual acuity. Often this primary repair is one of many further interventions required.

Consultation

Key stakeholders who reviewed this version:

- Director of Ophthalmology
- Director, Infection Management and Prevention service, Immunology and Rheumatology
- Clinical Pharmacist Lead - Antimicrobial Stewardship
- Medicines Advisory Committee – endorsed 20/10/2022

Definition of terms

Term	Definition
CHQ	Children's Health Queensland
CT	Computer tomography
ID	Infectious diseases
IMPS	Infection Management and Prevention service
IOFB	Intra-ocular foreign body
IOFT	Intra-ocular foreign trauma
IOP	Intra-ocular pressure
MRI	Magnetic resonance imaging
QCH	Queensland Children's Hospital
SAS	Special access scheme

References and suggested reading

1. Yildiz M et al. An important cause of blindness in children: open globe injuries. *J Ophthalmol*. 2016 Jan(6):1-5
2. Abbott J, Shah P. The epidemiology and etiology of pediatric ocular trauma. *Surv Ophthalmol*. 2013 Sep-Oct;58(5):476-85
3. Kuhn F, Morris R, Mester V, Witherspoon CD. *Ocular Traumatology*. Springer; 2008. 1.1 Terminology of mechanical injuries: the Birmingham Eye Trauma Terminology (BETT); p. [3-11].
4. Andreoli CH, Gardiner MF. Open globe injuries: Emergent evaluation and initial management. In: *UpToDate*, Waltham, MA. (Accessed March 8, 2017.)
5. Li, X, Zarbin MA, Bhagat N. Pediatric open globe injury: A review of the literature. *J Emerg Trauma Shock* 2015;8:216-223.
6. Ahmed Y et al. Endophthalmitis following open-globe injuries. *Eye (Lond)*. 2012 Feb; 26(2): 212–217.
7. Muller GG et al. Antifungals in eye infections: drugs and routes of administration. *Rev Bras Oftalmol*. 2013; 72 (2): 132-141
8. Felton T et al. Tissue penetration of antifungal agents. *Clin Micro Review*. 2014; 27 (1): 68-88
9. Riddell IV J et al. Treatment of Endogenous Fungal Endophthalmitis: Focus on New Antifungal Agents. *Clinical Infectious Diseases* 2011;52(5):648–653
10. Therapeutic Guidelines. Pre-emptive treatment following a penetrating eye injury. In: *Therapeutic Guidelines*, ed. Antibiotic; 2022.

Guideline revision and approval history

Version No.	Modified by	Amendments authorised by	Approved by
1.0 20/06/2019	Pharmacist Advanced – Antimicrobial Stewardship Director – Infection Management and Prevention service, Immunology and Rheumatology Pharmacist Advanced – Quality and Safety Director of Pharmacy	Children's Health Queensland Medicines Advisory Committee	Executive Director Clinical Services (QCH)
2.0 14/05/2020	Pharmacist Advanced – Antimicrobial Stewardship Director – Infection Management and Prevention service, Immunology and Rheumatology	Children's Health Queensland Medicines Advisory Committee (21/05/2020)	Executive Director Clinical Services (QCH)
3.0 25/08/2022	Clinical Pharmacist Lead – Antimicrobial Stewardship Director – Infection Management and Prevention service, Immunology and Rheumatology	Children's Health Queensland Medicines Advisory Committee (21/05/2020)	Executive Director Clinical Services (QCH)
4.0 18/10/2022	Clinical Pharmacist Lead – Antimicrobial Stewardship Paediatric Infection Specialist Director - Ophthalmology	Director, Infection Management and Prevention service, Immunology and Rheumatology	Divisional Director Medicine

Keywords

Open globe injuries; penetrating eye injuries, endophthalmitis, intravitreal, intracameral, antimicrobial stewardship, AMS, ID. Ophthalmology, vancomycin, ceftazidime, natamycin, voriconazole, cefazolin, cefalothin, gentamicin, amphotericin B, ofloxacin, ciprofloxacin, 01074

Accreditation references

NSQHS Standards (1-8): 3 Preventing and Controlling Healthcare Associated Infections, 4 Medication Safety